

Conformal Mapping of the Inner Colon Surface to a Cylinder for the Application of Prone to Supine Registration

Holger Roth¹

¹ University College London, UK

Jamie McClelland¹

² Medicsight PLC
London, UK

Darren Boone¹

Mingxing Hu¹

Sebastien Ourselin¹

Greg Slabaugh²

Steve Halligan¹

David Hawkes¹

Abstract

CT-Colonography is widely utilised in the diagnosis of colorectal cancer. However, the technique is difficult and time-consuming because residual stool may simulate colorectal cancer or potentially precancerous polyps. Consequently, scans are routinely performed with the patient in both prone and supine positions to help differentiate mobile faecal matter from fixed abnormalities of the colonic wall. Currently, the prone and supine datasets have to be manually aligned which can be very difficult due to the significant colonic deformation which takes place during patient movement. Establishing accurate spatial correspondence between prone and supine inner colon surfaces reconstructed from CT images can therefore potentially improve the accuracy and reduce the time taken for interpretation. This paper presents a method for mapping the inner colonic surface to a cylinder using the Ricci flow which provides a 2D indexing system over the full length of the colon. This procedure converts the registration task from a 3D to a 2D problem and could help cope with the large deformations occurring between prone and supine positions.

1 Introduction

Today, CT colonography, or virtual colonoscopy, has been established as a methodology for screening colorectal lesions in Europe, USA and Japan. Unlike traditional colonoscopy, which can have high miss-rates with small adenomas [8], CT imaging has the potential to enable examination of the whole colonic surface for lesions. This is done by imaging the patient in prone and supine positions to rearrange remaining fluids or a collapsed colon. Furthermore, the discomfort the patient suffers from is drastically reduced and there is considerably less danger of perforating the colon during the screening process. In order to achieve the best quality images, the bowel is prepared in accordance to current recommendations [10]. The administration of contrast agents even enables the digital cleansing of remaining faecal matter from the CT images. However, interpretation of CT colonography is difficult and time-consuming even for experienced readers. Retained faecal matter or anatomical structures such as thickened haustral folds can closely simulate pathology and lead to false positive diagnoses. This can be reduced if the information from both prone and supine images is taken into account. Currently, the radiologist still has to align both CT images manually which is a time-intensive and difficult task. Therefore, a method for establishing the spatial registration between both views has the potential to ease the process and increase the accuracy of the diagnosis. Several groups have attempted to register the prone and supine CT images of the colon using features or voxel-based approaches [11, 9, 6, 12]. However, it is difficult to identify features accurately and a very limited number of corresponding points are unable to cope with complicated deformation between prone and supine positions in a reliable way. Furthermore, based on our own studies, conventional non-rigid registration approaches based on image intensity cannot deliver a reliable and accurate result. These approaches cannot fully describe the deformation of the colonic surface.

These difficulties in establishing the spatial correspondence between both views in three-dimensional space motivates us to propose a method to simplify the registration task. The proposed method is based on a 2D parameterisation which represents the colon as a cylinder using a conformal one-to-one mapping. Hence, it converts the non-rigid 3D registration task to a 2D problem. This procedure has the potential to enable a better alignment of the inner colon surfaces in the prone and supine positions. In order to produce a 2D parameterisation of the inner colonic surface, we flatten the colon onto a 2D plane. The surface is repeated in radial direction, but not in the direction along the colon. Therefore, the surface is topologically cylindrical. Several methods to achieve this flattening have been proposed. This was originally done to produce better visualisations for examining the colonic surface in order to detect polyps [4]. Methods based on conformal mapping can give a one-to-one mapping of the entire surface onto planar space while minimising the local angular distortion. This preserves local shape attributes. This principle is illustrated in Fig. 1 where a surface S in R^3 is mapped to D in R^2 using a one-to-one mapping ϕ . The extracted inner colon surfaces need to be of genus-zero so they can be used with conformal mapping methods. We had to ensure this by manually editing some of the segmentations in order to achieve topologically correct surfaces. Furthermore, a point in rectum and cecum need to be selected manually to define the start and end of the cylindrical 2D representation.

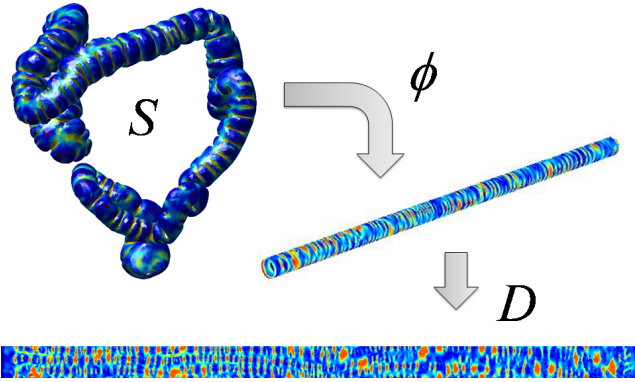


Figure 1: Mapping the inner colon surface onto a cylinder and 2D manifold, where the colour scale indicates the shape index (see section 2.3)

2 Methods

2.1 Parameterisation of the Inner Colon Surface

One possible conformal mapping to parameterise arbitrary discrete surfaces is the recently introduced Ricci flow method [1]. Qiu *et al.* [2] were the first to apply this method to the colon using volume rendering for the purpose of visualisation. We use the shape index SI (see section 2.3) to visualise anatomical features and ultimately guide a registration. The Ricci flow method deforms a surface based on its local curvature in order to achieve the parameterisation and can be defined by

$$\frac{du_i(t)}{dt} = \bar{K}_i - K_i, \quad (1)$$

where K_i is the local discrete Gaussian curvature of S and \bar{K}_i is the desired Gaussian curvature. u_i are the radii computed from a circle packing metric [3]. The Ricci flow can be regarded as the gradient flow of the Ricci energy [4]. This can be minimised using the steepest gradient descent method [5]. For the purpose of producing a mapping onto planar space, we set the local target curvatures \bar{K}_i to zero at all vertices.

2.2 Inner Colon Surface Extraction

We use the air inside the colon as segmented by the method described by Slabaugh *et al.* [6] to extract the inner colon surface. We had to ensure topologically correct segmentations by manually editing in order to achieve genus-zero surfaces. Future work will investigate automated topological correction. The marching cubes algorithm is then used to extract a discrete surface mesh. This is subsequently smoothed with a sinc-filter to achieve a continuous surface which converges (using the Ricci flow method). The mesh is also decimated using a quadric edge collapse in order to reduce computation time. Finally, a Loop subdivision is used to achieve uniformly sized and non-skewed faces. This results in a closed and simply connected genus-zero surface S which lies on the air/tissue border of the colon.

In order to parameterise S with the Ricci flow method we convert it to a genus-one surface SD [7]. Therefore, we define holes in the surface at manually identified points in rectum and




Figure 2: Computed planar embeddings with error $E_{\max} = 2e - 5$ rad (left), $E_{\max} = 5e - 6$ rad (middle) and $E_{\max} = 5e - 6$ rad averaged (right)

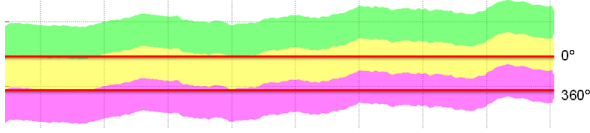


Figure 3: Sampling the unfolded mesh. The top and bottom bands represent the repetition of the planar embedded meshes D of the surface S . The raster-image I will fill the space between the two horizontal lines.

cecum. The remaining surface is doubled, inverted and glued with the original mesh on the vertices along the previously produced holes. The resulting surface SD is then parameterised using the Ricci flow.

2.3 Cylindrical Representation of the Inner Colon Surface

The Ricci flow converges to a planar 2D manifold D embedded in R^2 with its local Gaussian curvatures being near to zero everywhere. Once the maximum difference error E_{\max} between all K_i and \bar{K} is small enough, D can be computed, using the resulting edge lengths of each face. We start from a seed face and then iteratively add neighbouring faces similarly to [8]. However, we computed D using an averaging method which allows stopping the convergence earlier. We compute the position of each triangle vertex based on the intersection of two circles with radii equal to the corresponding edge lengths. This results in a planar mesh with cracks and overlapping faces as K_i is not exactly zero at every vertex. Those errors in computing the planar embedding are reduced as the Ricci flow converges to a lower error. Sections of 2D surfaces, computed from the same inner colon surface after different error levels E_{\max} , are shown in Fig. 2 (left) and Fig. 2 (middle). When the errors in the planar embedding are small enough, the Ricci flow can be stopped and corresponding vertices of neighbouring triangles can be joined together by averaging their 2D position. This is shown in Fig. 2 (right) and results in a closed mesh without cracks or overlaps. We want to generate a rectangular raster-image I which covers the full inner colon surface S . The x -direction is along the colon and y -direction is going radially around its circumference. However, D is not rectangular. Therefore, we repeat the mesh in the y -direction until it covers a rectangular region corresponding to the entire colon surface S as illustrated in Fig. 3. The top (0°) and bottom (360°) edges of the images correspond to the same line along the surface S .

Each pixel value of I can be any measurement computed on the colon surface S , or could potentially be any measurement computed from the original CT voxel data in the region of S . Here, the intensity values are interpolated from the shape index (SI) computed at each vertex of S . The shape index is defined as $SI \equiv \frac{1}{2} - \frac{1}{\pi} \arctan \left(\frac{\kappa_1 + \kappa_2}{\kappa_1 - \kappa_2} \right)$, where κ_1 and κ_2 are principal curvatures computed on S . The resulting images for the prone and supine

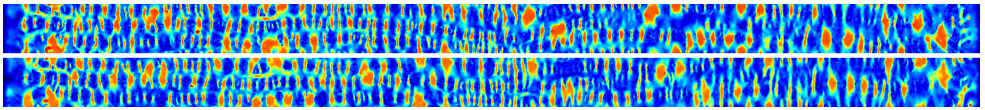


Figure 4: Prone (top) and supine (supine) images of the inner colon surface with the shape index as intensity.

position of the patient with dimensions of $n_x = 3000$ and $n_y = 150$ pixels are shown in Fig. 4. Corresponding features, like haustral folds, flexures or the teniae coli are clearly visible in both images. These images could be aligned using an intensity-based non-rigid registration method. This will establish the full spatial correspondence between the inner colon surfaces extracted from the two CT images and can be mapped back into three-dimensional space using the mapping ϕ .

3 Summary and Future Work

We have presented a method for mapping the inner colon surface to a cylindrical 2D manifold in order to simplify the prone to supine registration task. This is done using a one-to-one conformal mapping of the entire inner colon surface. One dimension corresponds to distance along the colon and the other to its angular orientation. This indexing system will be used to simplify the registration task from a 3D- to a 2D-problem. From the parameterisation we can compute an image I . Each pixel in I corresponds to a position in three-dimensional space and is assigned the value of the local shape index computed on the 3D surface. These images generated from the prone and supine views could be used to guide a non-rigid intensity-based registration in order to establish full spatial correspondence between the prone and supine inner colon surfaces.

We are currently investigating a non-rigid method for establishing the spatial correspondence between the colon surfaces extracted from the prone and supine CT scans, based on the method of producing 2D parameterisations of both surfaces proposed here. This is based on the method of producing 2D parameterisations of both surfaces proposed here. Furthermore, we will investigate automated topological correction of the colon segmentation. This is in order to increase robustness and deal with insufficient distention where the colon surface is collapsed. We will also explore the effects of varying parameters of the surface extraction. It will also be interesting to extend the proposed framework to include shape, intensity or statistical information from the original CT-images.

References

- [1] B. Acar, S. Napel, DS Paik, P. Li, J. Yee, CF Beaulieu, and RB Jeffrey. Registration of supine and prone ct colonography data: Method and evaluation. *Radiology*, 221:332, 2001.
- [2] B. Chow and F. Luo. Combinatorial Ricci flows on surfaces. *J. Differential Geom*, 63 (1):97–129, 2003.
- [3] M. Jin, J. Kim, F. Luo, and X. Gu. Discrete surface ricci flow. *IEEE Transactions on Visualization and Computer Graphics*, 14(5):1030–1043, 2008.

-
- [4] K. Johnson, C. Johnson, J. Fletcher, R. MacCarty, and R. Summers. CT colonography using 360-degree virtual dissection: a feasibility study. *AJR Am J Roentgenol.*, 186: 90–95, 2006.
 - [5] J. Lamy and R.M. Summers. Intra-patient colon surface registration based on teniae coli. In *SPIE Medical Imaging*, pages 116–123, 2007.
 - [6] J. Näppi, A. Okamura, H. Frimmel, A. Dachman, and H. Yoshida. Region-based supine-prone correspondence for reduction of false positive cad poly candidates in ct colonography. *Academic Radiology*, 12:695–707, 2005.
 - [7] F. Qiu, Z. Fan, X. Yin, A. Kaufman, and X.D. Gu. Colon Flattening with Discrete Ricci Flow. *MICCAI workshop*, pages 97–102, 2008.
 - [8] D.K. Rex, C.S. Cutler, G.T. Lemmel, E.Y. Rahmani, D.W. Clark, D.J. Helper, G.A. Lehman, and D.G. Mark. Colonoscopic miss rates of adenomas determined by back-to-back colonoscopies. *Gastroenterology*, 112(1):24–28, 1997.
 - [9] G. Slabaugh, X. Yang, X. Ye, R. Boyes, and G. Beddoe. A Robust and Fast System for CTC Computer-Aided Detection of Colorectal Lesions. *Algorithms*, 3(1):21–43, 2010.
 - [10] J.W. Suh and C.L. Wyatt. Deformable Registration of Supine and Prone Colons for Computed Tomographic Colonography. *Journal of computer assisted tomography*, 33 (6):902, 2009.
 - [11] S.A. Taylor, A. Laghi, P. Lefere, S. Halligan, and J. Stoker. European Society of Gastrointestinal and Abdominal Radiology (ESGAR): consensus statement on CT colonography. *European Radiology*, 17(2):575–579, 2007.